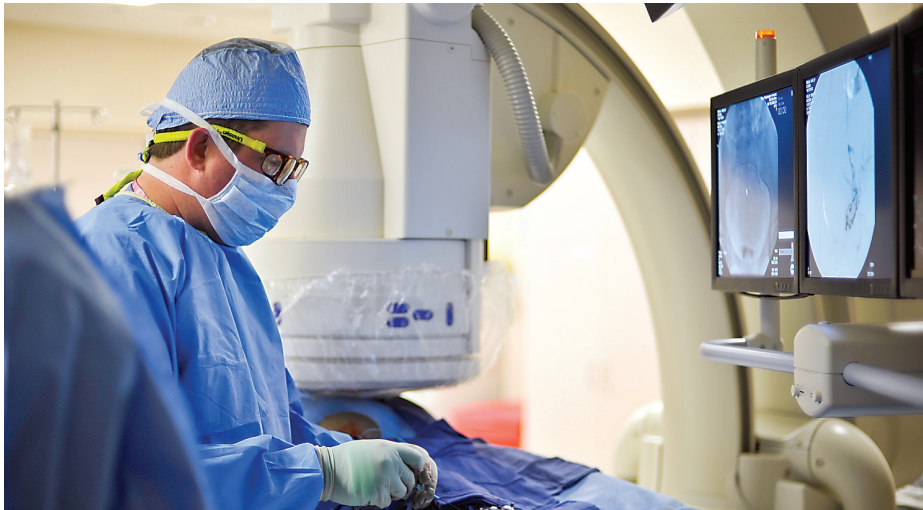

Photo by Rebecca Sell



VIVA's R. Donald Doherty Jr., MD, performs a UFE.

Uterine Fibroid Embolization Offers “Safe and Effective” Treatment

Uterine fibroid embolization (UFE), also referred to as uterine artery embolization, is gaining increased attention as an alternative to hysterectomy for symptomatic uterine fibroids. Authoritative medical reports indicate it is safe, effective and increasingly covered by insurance.

One of the most important reports evaluating the treatment is The American College of Obstetricians and Gynecologists August 2008 *Practice Bulletin* (“Alternatives to Hysterectomy in the Management of Leiomyomas”). The bulletin concludes that “based on long- and short-term outcomes, uterine artery embolization is a safe and effective option for appropriately selected women who wish to retain their uteri.”

Interventional radiologists with Virginia Interventional and Vascular Associates (VIVA) have been performing UFEs locally for the past decade with a high (97 percent) technical success rate, said R. Donald Doherty Jr., MD. During the minimally invasive procedure, physicians thread a catheter through the patient’s femoral artery to embolize targeted arteries, resulting in fibroid devascularization and involution.

“UFE is a safe, proven treatment for uterine fibroids with excellent short- and long-term outcomes based on consistent Level A scientific research,” noted Dr. Doherty. “Most women with symptomatic fibroids are candidates, regardless of fibroid size.”

VIVA is the interventional radiology group of Radiologic Associates of Fredericksburg (RAF). Its interventional radiologists are board certified and fellowship trained in percutaneous interventions using guided imaging. In addition to Dr. Doherty, VIVA physicians include Michael P. McDermott, MD, who heads the group; John J. McLaughlin, MD; John D. Statler, MD; and Victor J. D’Addio, MD.

Indications and Contraindications

Dr. Doherty noted most women with symptomatic fibroids are potential candidates for UFE. Typical symptoms include all or some of the following: heavy menstrual bleeding,

Uterine Fibroid Embolization continued page 2

Imaging Update

Digital Mammography Increases Accuracy

The Imaging Center for Women converted from analog mammography to digital mammography in October 2007. Since then, Radiologic Associates of Fredericksburg has reported the enhanced ability to visualize low-density calcifications in high-density breasts. Mammogram films of high-density breasts are more difficult to read because dense breasts have less fat than glandular and connective tissue.

“Low-density calcifications can look like four or five tiny speckles of salt when reading a mammogram. The quality of digital mammography makes them much easier to find in dense breast tissue,” said Aye Min, MD, of Radiologic Associates of Fredericksburg, one of the center’s eight dedicated radiologists.

The Imaging Center for Women is a partnership between RAF and MediCorp. Donald Allen, MD, RAF radiologist and medical director of the center, said the facility is among an estimated 49 percent nationwide that have converted to digital mammography. Conversion is a relatively expensive process, but one that the center was poised to make after studies confirmed the efficacy of digital mammography.

“We felt the quality of images was so much greater and interpretation was so much easier with digital mammography. You can see calcifications better and the images have much more contrast and therefore detail. Studies have shown that digital mammography is particularly effective for imaging women who are younger than 50, and those with dense breasts,” according to Dr. Allen.

Digital Mammography continued page 3

Radiologist Spotlight



Neil Patil, MD, MPH

Ask one of the newest members of Radiologic Associates of Fredericksburg what he finds most exciting about the field of radiology, and you won't hear about any one area of clinical interests, cases or research. Dr. Neil Patil enjoys it all.

"I like working with leading-edge modalities and interacting with patients," Dr. Patil said. "Everything is interesting about what we do. I enjoy my day."

Dr. Patil, age 32, joined RAF on July 1, 2008. He is board certified by the American Board of Radiology. His current clinical focus includes body imaging (CT, ultrasound, MRI and "virtual colonoscopy") and women's imaging (mammography, breast MRI and breast interventions such as stereotactic and ultrasound-guided biopsies). As part of his work, Dr. Patil frequently discusses results with breast imaging patients, and collaborates regularly with oncologists, breast surgeons and other referring physicians.

Born in Pune, India, Dr. Patil was four years old when he and his family moved to South Florida. His last name is pronounced Pa – TILL. "I tell people to think about the word 'until,' then say my name," Dr. Patil quipped.

He earned his bachelor of science degree from the University of Florida in Gainesville, graduating summa cum laude with a major in interdisciplinary studies and concentration in the neurobiological sciences. Dr. Patil earned a master's degree in public health from the University of South Florida in Tampa before heading to USF's medical school, where he received his doctorate in medicine in 2002. Dr. Patil then spent his transitional year at Christiana Health Care System in Wilmington, DE, and completed his diagnostic radiology residency at University of Medicine & Dentistry of New Jersey-Robert Wood Johnson University Hospital in New Brunswick, NJ.

Dr. Patil completed his abdominal imaging Fellowship at Duke University Medical Center in Durham, NC. ■

Uterine Fibroid Embolization continued from page 1

bleeding between periods, pelvic pressure, pelvic pain, urinary frequency, nocturia, leg and back pain, constipation, and painful intercourse.

The procedure has relatively few contraindications. Active pregnancy and a severe, life-threatening allergic reaction to the x-ray contrast medium are absolute contraindications, according to Dr. Doherty.

Procedure Overview

VIVA provides longitudinal services for uterine fibroid patients, including UFE evaluation, treatment, interventional radiology (IR) service admission, and clinical follow-up. The group works closely with referring physicians on individual cases.

During a UFE, an interventional radiologist makes a small incision in the patient's groin, inserting a catheter into the femoral artery. Using a high-definition x-ray camera for guidance, the physician threads the catheter through the patient's femoral artery and then releases an embolic agent (polyvinyl particles) into the uterine arteries that supply blood to the fibroid tumor. This blocks blood flow to the fibroids and results in the eventual shrinkage and death of fibroid tissue.

VIVA operates an outpatient office where patients are seen for initial consults and clinical follow-up. The procedure itself is performed in the IR suite at Mary Washington Hospital. A local anesthetic is applied to the small incision site while the patient is conscious, but sedated. UFEs do not require general anesthesia.

UFE usually requires a hospital stay of one night. Medications are prescribed following the procedure to treat cramping and pain. Many women resume light activities in a few days, and return to normal activities within seven to ten days, according to the Society of Interventional Radiology (SIR).

Safety, Efficacy and Reimbursement

SIR's website provides the following data on the safety, efficacy and insurance reimbursement of UFEs.

- On average, 85 - 90 percent of women who undergo UFEs experience significant or total relief of heavy bleeding, pain and/or bulk-related symptoms.
- Recurrence of treated fibroids is rare. Short and mid-term data show UFE to be highly effective with a low rate of recurrence. Long-term (10-year) data are not yet available, but in one study in which patients were followed for six years, no growth returned after embolization.
- Numerous pregnancies have been reported after the UFE procedure; however, prospective studies are needed to determine the effects of UFE on a woman's ability to have children.
- Less than 2 percent of patients have entered menopause as a result of UFE. This is more likely to occur if the woman is in her mid-forties or older and is already nearing menopause.
- UFE is a safe method and, like other minimally invasive procedures, has significant advantages over open surgery. However, as with any surgery, UFE comes with some associated risks. A relatively small number of patients have experienced infection, which usually can be controlled by antibiotics. There also is a less than 1 percent chance of injury to the uterus.
- Most major insurers cover UFEs for symptomatic fibroids.

Future Treatments

Magnetic resonance-guided focused ultrasound is another procedure that is also being evaluated by VIVA for treatment of uterine fibroids. The procedure is FDA approved for treating uterine fibroids, but is relatively new and not cost-effective at present, Dr. Doherty noted. Most insurers do not cover the procedure. ■

For more information contact R. Donald Doherty Jr., MD at richard.doherty@medicorp.org or Michael P. McDermott, MD at michael.mcdermott@medicorp.org or call (540) 361-1000 and leave a message.

To make suggestions for future stories, contact Irene Valentino at (540) 361-1000 or ivalentino@rafadmin.com .

“Virtual Colonoscopy” Proving Important Screening Tool

Computed tomographic (CT) colonography, also referred to as virtual colonoscopy, is providing local clinicians with a minimally invasive screening tool for detecting early colorectal cancer and polyps.

Christopher Meyer, MD, radiologist and member of the virtual colonoscopy team at Radiologic Associates of Fredericksburg, said gastroenterologists refer patients who have experienced incomplete optical colonoscopies. Physicians also refer patients with contraindications to optical colonoscopy, including the following: severe cardiac or pulmonary disease, as there is an increased risk with sedation; bleeding disorders or the inability to be taken off anticoagulation therapy; and/or known stricture or stenosis. In addition, the procedure provides clinicians with an option for screening patients who refuse to undergo conventional colonoscopy.

The efficacy and safety of virtual colonoscopy have been evaluated in a number of studies. Final results of the American College of Radiology Imaging Network National CT Colonography Trial, published in the Sept. 18, 2008 New England Journal of Medicine (NEJM), concluded that “...CT colonographic screening identified 90% of subjects with adenomas or cancers measuring 10 mm or more in diameter. These findings augment published data on the role of CT colonography in screening patients with an average risk of colorectal cancer.” Other key research includes a large-scale study by the University of Wisconsin School of Medicine, published in the Oct. 4, 2007 NEJM, which found that virtual colonoscopy and optical colonoscopy screening resulted in similar detection rates for advanced neoplasia.

Based on mounting research, the American Cancer Society, the American College of Radiology and the U.S. Multi-Society Task Force on Colorectal Cancer, which included representatives from three gastroenterology groups, added virtual colonoscopies to their lists of recommended tests in 2008.

“Virtual colonoscopy has become another important screening modality in the arsenal of procedures for detecting colon polyps and early colon cancer,” Dr. Meyer noted.

Virtual colonoscopy also allows radiologists to examine other intraabdominal organs. Occult intraabdominal malignancy, abdominal aortic aneurysms, renal stones, gallstones and intraabdominal adenopathy have all been identified using the procedure.

Contraindications

Patients with abnormal virtual colonoscopies often must undergo an optical colonoscopy later to evaluate or remove suspicious lesions and polyps. Therefore, virtual colonoscopies are intended for patients with an average risk of colorectal cancer and are contraindicated for patients with a history of polyps or colon cancer.

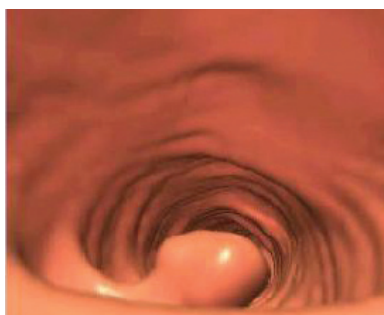
Other contraindications include the following: active rectal bleeding or other symptoms that suggest an increased likelihood of finding a polyp or cancer; acute diverticulitis, which increases the risk of perforation; active bowel inflammation (active ulcerative colitis, Crohn’s disease, diverticulitis, or inflammatory bowel disease, as it increases the risk of perforation); pregnancy; recent colectomy or polypectomy; lack of intact ileocecal valve or right hemicolectomy; absence of anorectum; and/or severe pain or cramping on the day of exam.

Experience and Training

RAF’s virtual colonoscopy team has performed the procedure for two years at Medical Imaging at Lee’s Hill in Fredericksburg. In addition to Dr. Meyer, team members include George Fish, MD; Jeffrey Frazier, MD; Stacy Moulton, MD; and Neil Patil, MD.

These physicians have all completed additional continuing medical education workshops, reviewed National Institutes of Health case files and/or received additional training through residency or fellowship programs. Their daily experience reading normal and abnormal abdominal CT scans also comes into play when evaluating virtual colonoscopies.

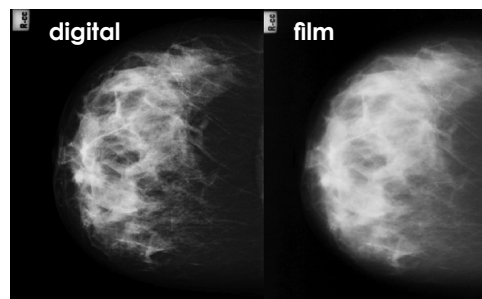
Virtual Colonoscopy continued page 4



Virtual colonoscopy image showing polyp

Image courtesy of the American College of Radiology

Digital Mammography continued from page 1



Comparison of digital and film mammogram. Questionable area, just below the nipple, is more easily visible in the digital image.

Image courtesy of UNC-Chapel Hill School of Medicine Department of Radiology, Breast Imaging

A landmark study published in a special online edition of the New England Journal of Medicine on Sept. 16, 2005 concluded that the “overall diagnostic accuracy of digital and film mammography as a means of screening for breast cancer is similar, but digital mammography is more accurate in women under the age of 50 years, women with radiographically dense breasts, and premenopausal or perimenopausal women.” The study, known as the American College of Radiology Imaging Network Digital Mammographic Imaging Screening Trial (DMIST), estimated that digital mammography was up to 28 percent more effective at detecting breast cancer in these populations. Results were based on evaluations of more than 42,000 asymptomatic women who received both film and digital examinations at 33 sites in North America.

Digital mammography also simplifies the process of sharing results with referring physicians and comparing mammograms over time, Dr. Allen noted. In addition, digital mammography enables digital storage and transfer capabilities that are becoming increasingly important in the healthcare industry.

Experience and Training

Radiologists at The Imaging Center for Women read more than 30,000 mammograms annually, making it one of the busiest facilities in the state. To prepare for the conversion to digital mammography, Drs. Allen and Min visited the facility of the lead researcher for DMIST, Etta Pisano, MD, of the University of North Carolina, Chapel Hill. Radiologists and technicians at The Imaging Center for Women also received special training through continuing medical education to meet the standards of the American College of Radiology. ■

For more information contact Donald Allen, MD at donald.allen@medicorp.org or Aye Min, MD at aye.min@medicorp.org or call (540) 361-1000 and leave a message.

www.imagingway.com
(540) 361-1000

Ed Swager, Chief Executive Officer

Radiologic Associates of Fredericksburg (RAF) is the largest provider of medical imaging services in Central Virginia including Fredericksburg, Stafford and Spotsylvania. RAF's interventional radiology group, Virginia Interventional and Vascular Associates (VIVA), performs minimally invasive procedures.

RAF publishes *Imaging Advances* periodically for referring physicians and the greater medical community. For more information, please contact Irene Valentino, RAF Project Manager, ivalentino@rafadmin.com, (540) 361-1000.

Imaging Advances is produced by Health Industry Writers, a division of Susan Carol Associates Public Relations

Radiologic Associates of Fredericksburg
10401 Spotsylvania Avenue, Suite 200
Fredericksburg, VA 22408

return service requested

VIVA
Virginia Interventional & Vascular Associates

Experienced, Board Certified Interventional Radiologists

- Michael P. McCormick, M.D. >>
- John E. MacLennan, M.D. >>
- R. Donald Doherty, Jr., M.D. >>
- John D. Reiter, M.D. >>

[PATIENTS](#)
[SERVICES](#)
[PHYSICIANS](#)
[NEWS & RESEARCH](#)
[CONTACT US](#)
[HOME](#)

[PATIENT RESOURCES](#)
[PHYSICIAN RESOURCES](#)
[NEWS & RESEARCH](#)

Virtual Colonoscopy continued from page 3

Procedure Overview

Virtual colonoscopy patients must undergo bowel preparations similar to those for optical colonoscopy, where the goal is a “clean, distended bowel” for the procedure, said Dr. Meyer. Patients meet with the group’s CT screening coordinator beforehand to receive instructions and items they will need for the prep.

A 40-slice CT scanner and a carbon dioxide (CO2) insufflator are used during the virtual colonoscopy, which takes approximately 20 minutes to complete. First, a catheter with an inflatable balloon tip is inserted into the patient’s rectum and filled slowly with CO2, regulated by an automatic turnoff. This ensures a well-distended bowel.

The patient then is scanned in the supine position and in the prone position. Resulting images are sent to the radiologists’ workstations, where axial and sagittal plane images are used to reconstruct a three-dimensional visualization—or “fly-through”—of the entire colon and rectum. Each virtual colonoscopy is read by two team members for improved accuracy, Dr. Meyer said.

Reimbursement Considerations

Insurance companies may pay for diagnostic virtual colonoscopies in cases of incomplete colonoscopy, noted Carla Ford-Brooks, CT screening coordinator. Most insurance companies do not presently cover the cost if a patient is opting to have the procedure done as a screening, but may reimburse if the patient is referred due to a contraindication, including risks from coagulation therapy or anesthesia. ■

For more information, contact Christopher Meyer, MD at christopher.meyer@medicorp.org or Jeffrey Frazier, MD at jeffrey.frazier@medicorp.org or call (540) 361-1000 and leave a message.

www.imagingway.com

Referring Physician Resources: Online Enhancements

RAF is expanding its online resources. Based on small group meetings with referring physician offices and patients, RAF launched a website for its interventional radiology group, VIVA. RAF also streamlined navigation of its central website and added information of interest to physicians.

Visit www.imagingway.com to access the RAF and VIVA websites for online resources, including patient information materials and forms.

DOWNLOAD VIVA
PDF FILE

Phone: (540) 654-8118
www.vivadiagnostics.com

1018 Sun Pier Blvd, Suite 200
Fredericksburg, Virginia 22401
Over 1000 Hwy 101/201
Hwy 101/201

Office Hours:
8 am - 5 pm, Mon - Fri

Virginia Interventional and Vascular Associates (VIVA), the Fredericksburg area's only interventional radiology practice. We are part of Radiologic Associates of Fredericksburg.

As interventional radiologists, our doctors combine their skills in reading medical images and performing procedures to diagnose and treat a variety of medical conditions:

- Peripheral vascular disease
- Compression fractures from osteoporosis
- Cancer therapies
- Varicose veins
- Kidney disease/tumors
- Heavy metal diseases
- Uterine fibroids

We specialize in minimally invasive procedures that provide patients with possible alternatives to major surgery. Our doctors also perform procedures supporting traditional cancer and dialysis treatments.

Most interventional radiologists are located near major urban medical centers. VIVA doctors live and work in our local community, offering patients and referring physicians:

- High-end expertise. Hometown touch.
- Rapid recovery. Rapid results.
- Referring Physician support. Timely reports.
- Easy access. Convenient location.
- Board certified, fellowship trained, CAQI certified physicians.
- A specialty usually located only near major urban medical centers.
- In outpatient facility, one of the best in VA.